

# Live surgery - 4

- Case: Post traumatic tendo Achilles tear left ankle
- Procedure: Tendo Achilles repair + retrocalcaneal spur excision +/- flexor hallucis tendon transfer left ankle



# **BRIEF HISTORY**

- C/o **Left heel** pain since 3 days
- C/o difficulty in walking since 3 days
- History of direct trauma to the back of ankle 3 days back
- Previous history of pain in the same heel since 1 year

# EXAMINATION-

## LEFT ANKLE

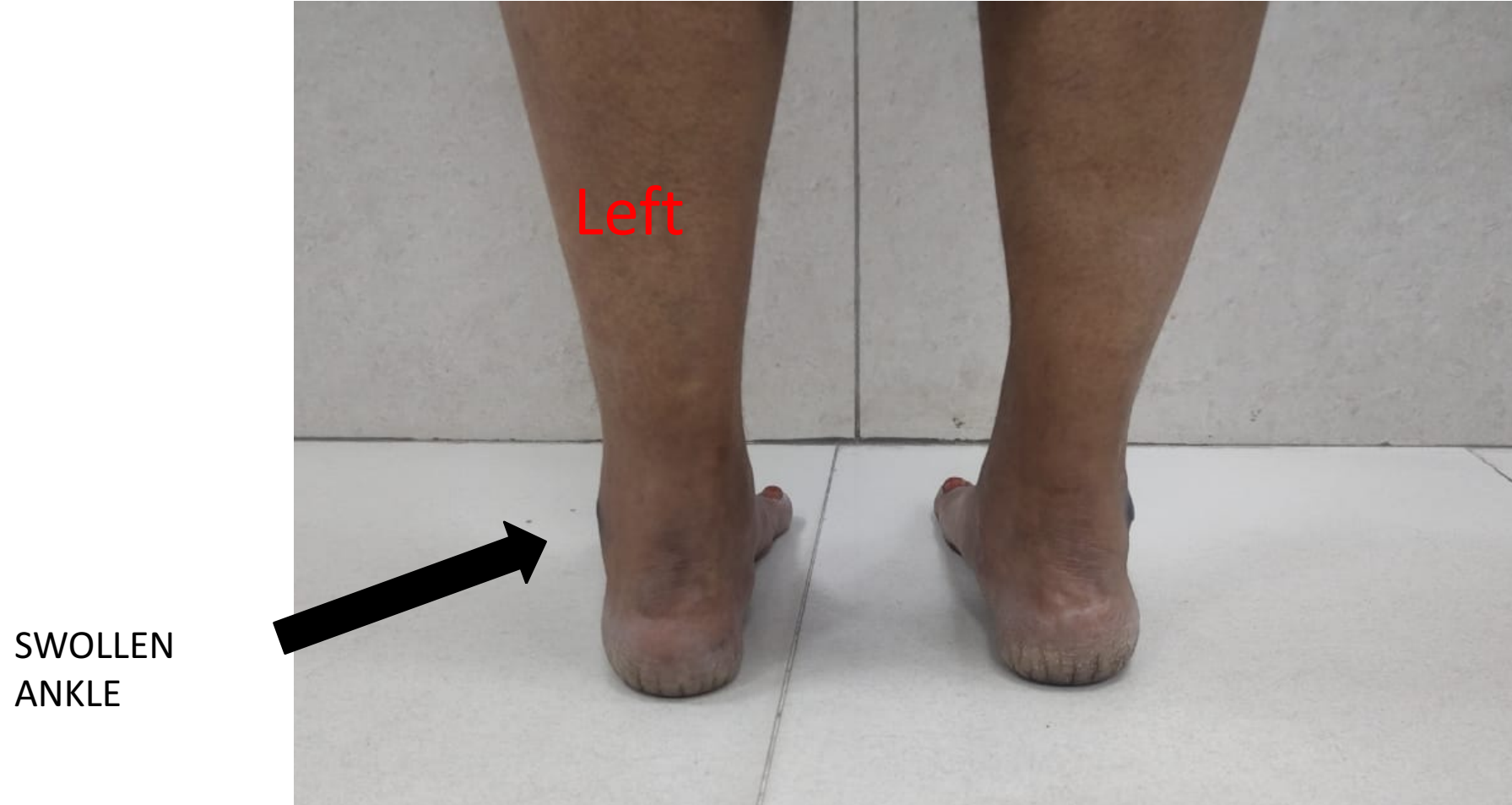- Gait analysis - antalgic gait with no push off and patient drags her foot while walking
- Inspection – swelling + over posterior aspect of left ankle
- Palpation - plantar flexion : 0 - 25°
  - Dorsiflexion : 0 - 10° active and 0 -25° passive
  - Inversion& eversion : normal

• **SPECIAL TESTS-**

Left ankle

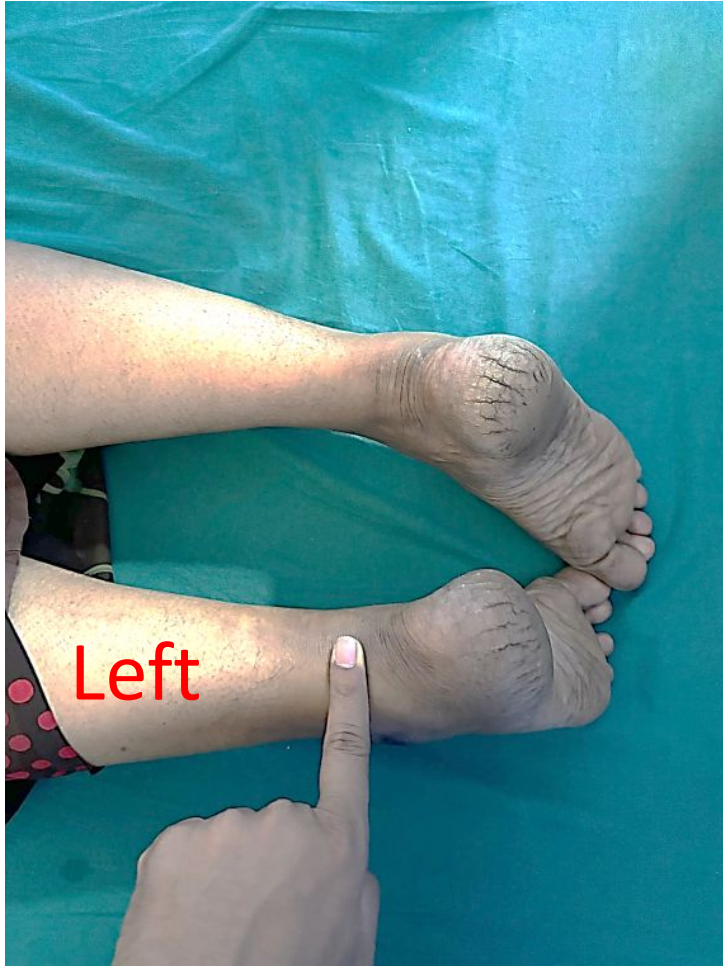1. THOMPSON'S TEST– POSITIVE
2. SINGLE-LEG HEEL RAISE TEST – POSITIVE
3. MATLE'S TEST– POSITIVE

# CLINICAL PICTURES

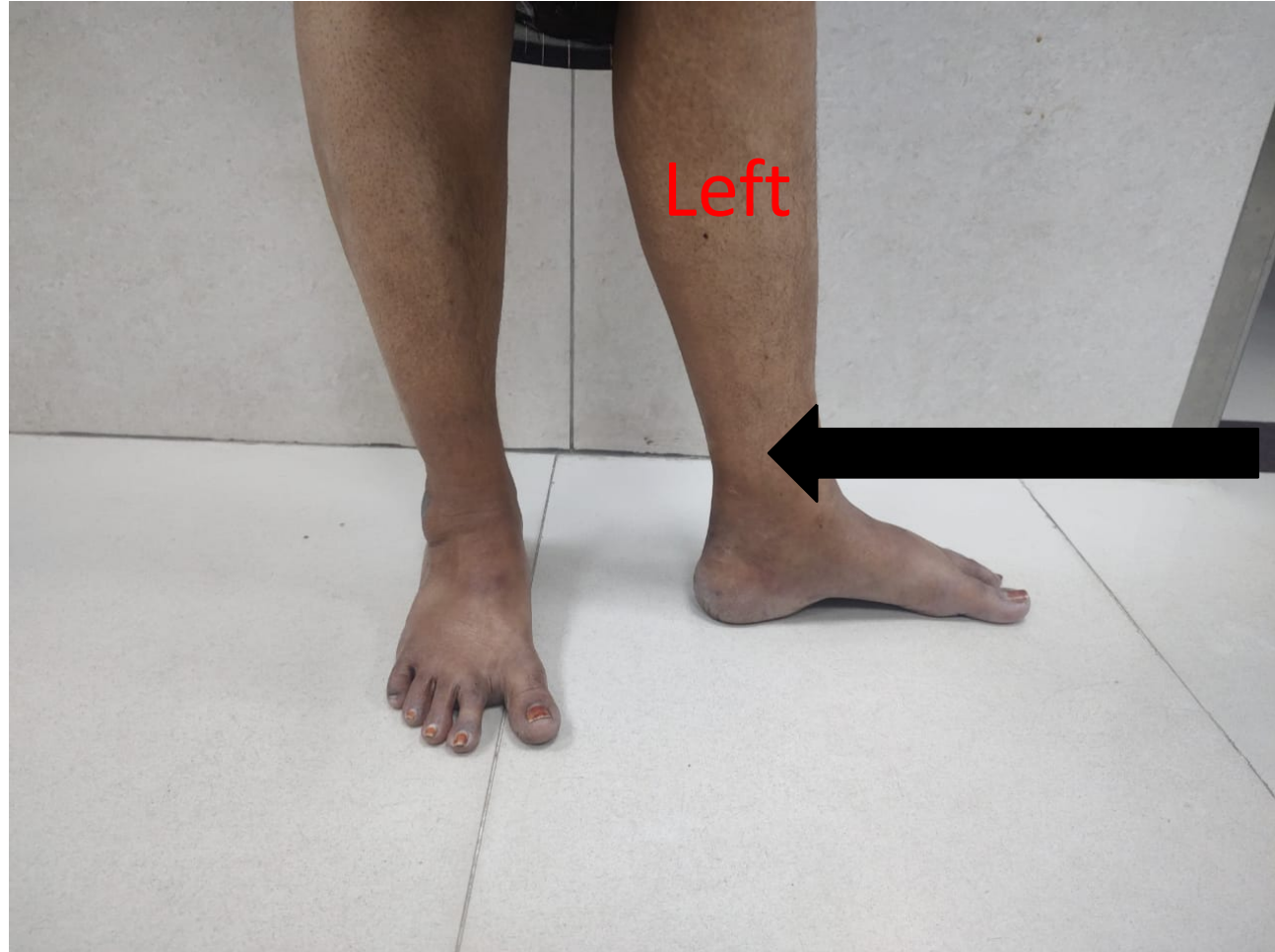

Left ankle affected side

## Left ankle affected side



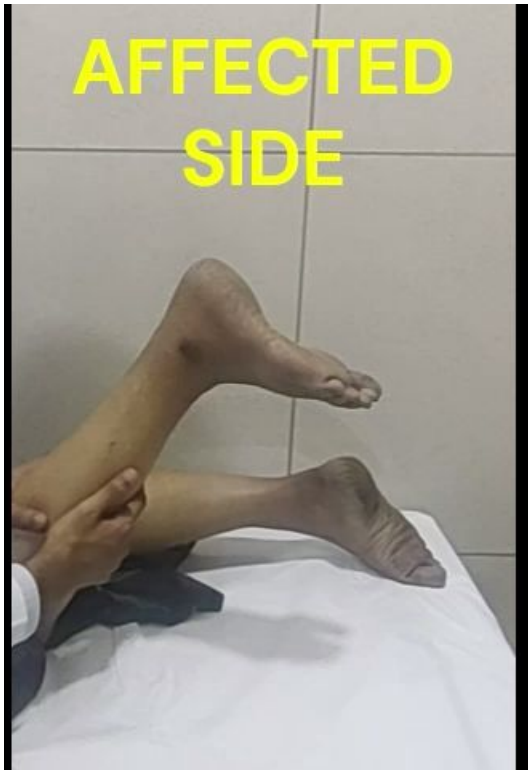PALPABLE  
DEFECT DUE TO  
TENDON TEAR



NOTICEABLE  
DEFECT DUE  
TO TENDON  
TEAR

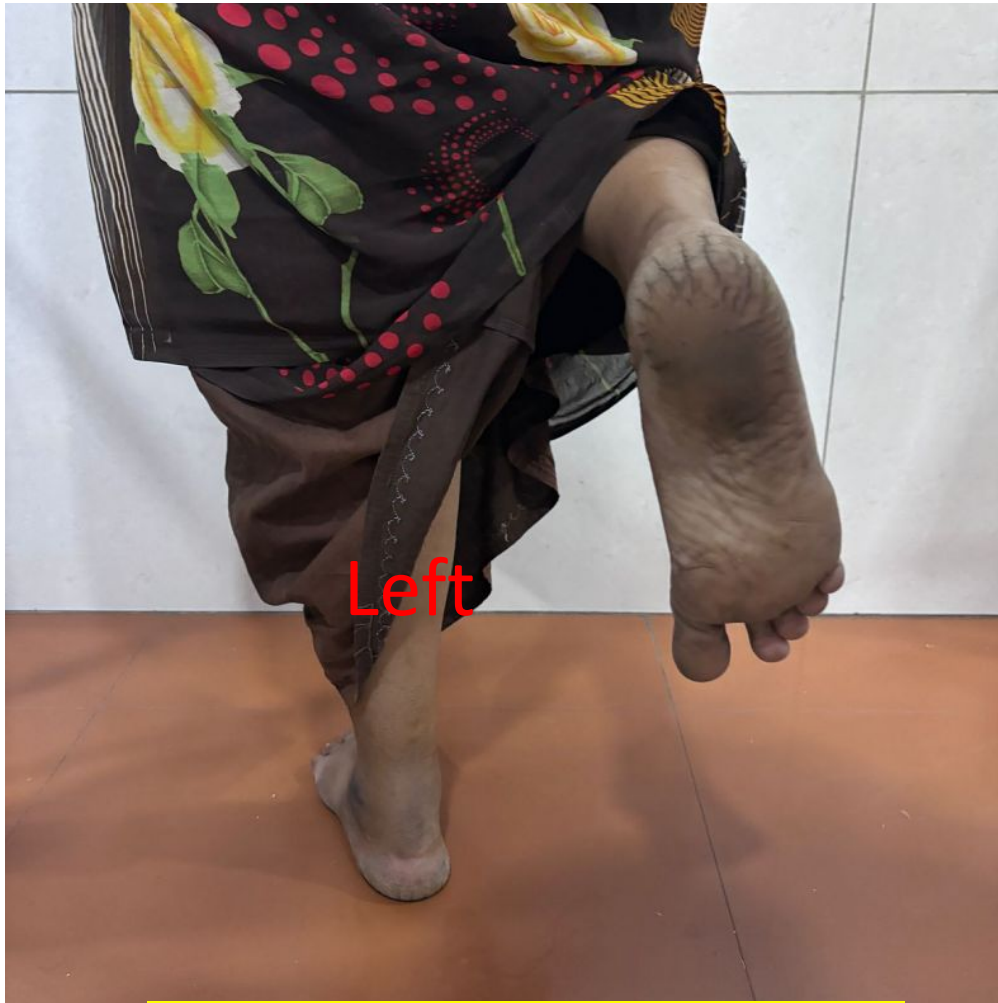# Left ankle affected side

Thompson`s test

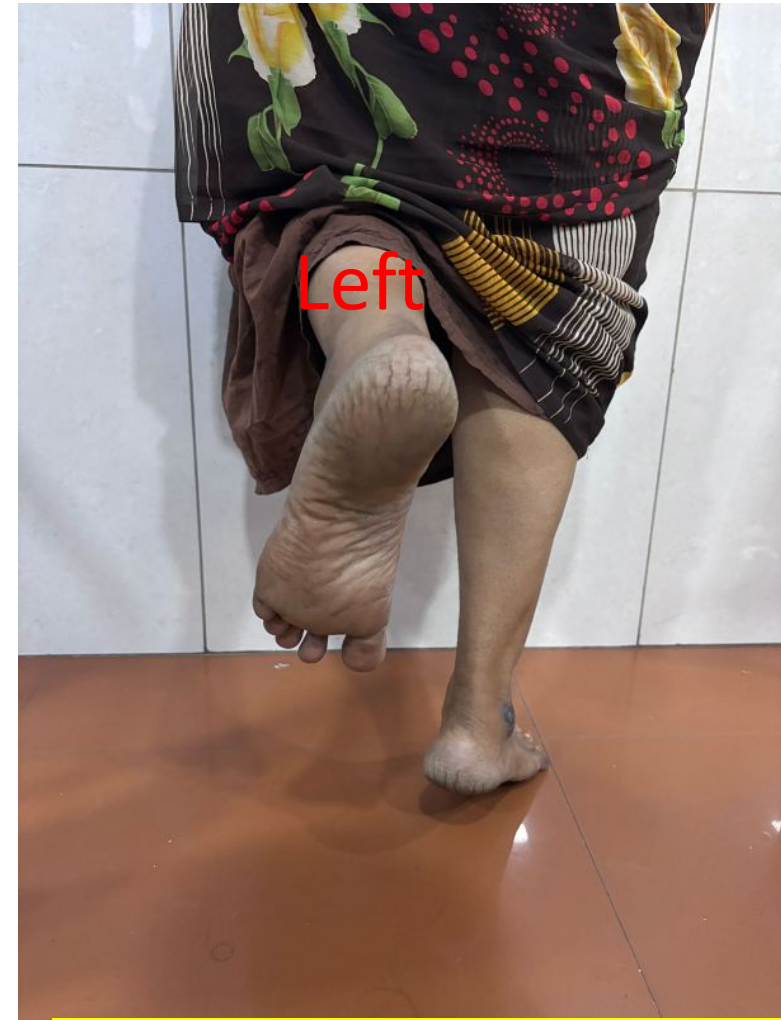

No push-off while walking on the Left side





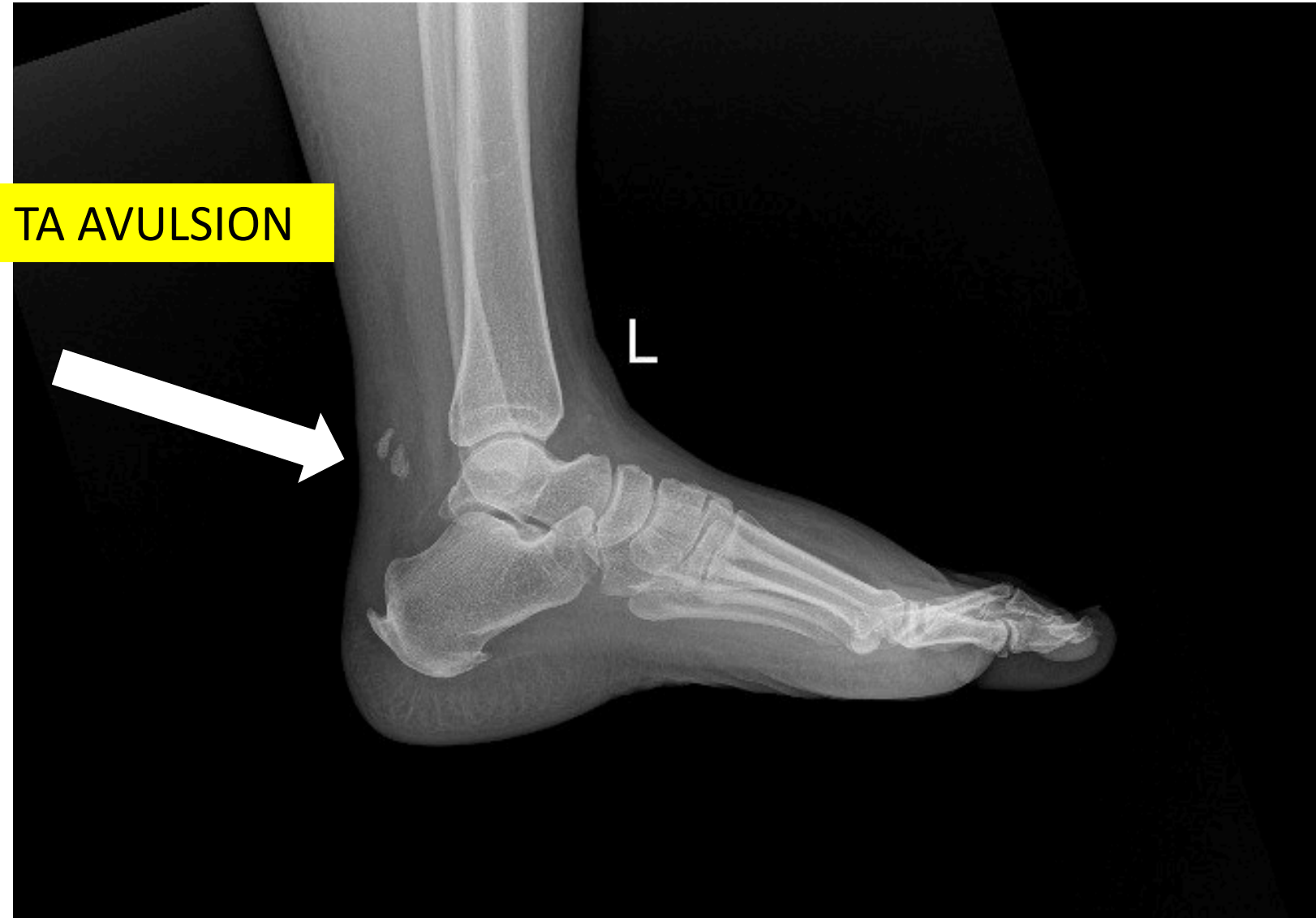
TIP TOE STANDING NOT POSSIBLE  
ON LEFT SIDE



TIP TOE STANDING POSSIBLE ON  
RIGHT SIDE



# PRE-OP XRAY



# ULTRASOUND REVEALED COMPLETE RUPTURE WITH 5 CM RETRACTION

## USG – LEFT TENDOACHILLES

### FINDINGS :

- Complete tear of Left tendoachilles is near its insertion site. Dense echogenic areas with posterior acoustic shadowing seen in the tendon at about 6cm proximal to the insertion - suggestive of calcifications.
- There is gap of 5cm between retracted torn ends. Areas of hematoma noted within distal tendon.
- Intact attached tendon at its insertional site measures ~9mm.
- Mild fluid noted in retrocalcaneal bursa- likely bursitis.

### IMPRESSION :

- Features are suggestive of tendoachilles tear, as detailed.

# Plan -

- Surgeon: Dr SR SUNDARARAJAN
- Moderators : Dr Mahendra Kudchadkar, Dr Shivam shah
- Case: POST TRAUMATIC TENDOACHILLES TEAR LEFT ANKLE
- Procedure: TENDOACHILLES REPAIR + RETROCALCANEAL SPUR EXCISION +/- FHL TENDON TRANSFER LEFT ANKLE

